

Surveillance Renal Transplant Biopsies: Useful or Irrelevant

Bennett WM, Simonich E, Garre AM, Demirel S, Marksthaler ME, Batiuk TD
Legacy Transplant Services, Legacy Good Samaritan Medical Center, Portland, OR

BACKGROUND

Performance of surveillance biopsies in kidney transplantation remains somewhat controversial. There are many centers that biopsy patients based only on rises in serum creatinine or symptoms and others who exclude subclinical rejection by protocol biopsies. In the future surveillance biopsies may be useful in molecular prognosis but at present evidence of acute rejection although subclinical is treated with high dose steroids.^{1,2}

METHODS

Since 2011 we have performed surveillance biopsies at 2 months and 6 months post-transplant with follow up at 1 year for any abnormal results. Immunosuppression was Thymoglobulin induction (3 mg/kg) followed by tacrolimus, mycophenolate and prednisone. This regimen was occasionally changed to azathioprine, sirolimus, or cyclosporine based on side effects of the original regimen.

RESULTS

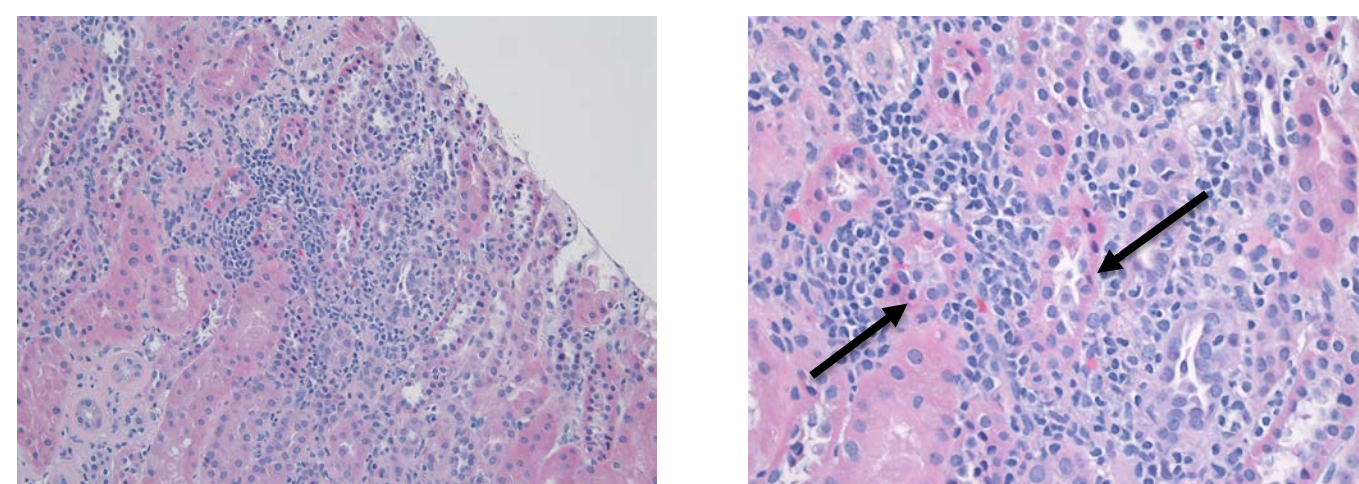
In 624 of the 663 cases, C4d was available. 78 (12.5%) were positive with 31 occurring in the surveillance biopsies. Thus, there were many C4d positive patients without concurrent histologic evidence of antibody mediated rejection. There was 1 major bleeding complication requiring evacuation of a transplant kidney hematoma. If a surveillance biopsy showed acute rejection a course of steroids was given. There were no **subclinical** antibody mediated rejections.

TABLE 1

Surveillance Biopsies n=422		For Cause Biopsies n=241	
Subclinical rejection or "borderline changes"	54 (12.7%)	Clinical rejection or "borderline"	139 (58%)
Other changes probably donor derived	3 (0.6%)	Other changes	13 (5.4%)
Antibody mediated rejection	0	Antibody mediated rejection	6 (2.5%)

CASE STUDY 1

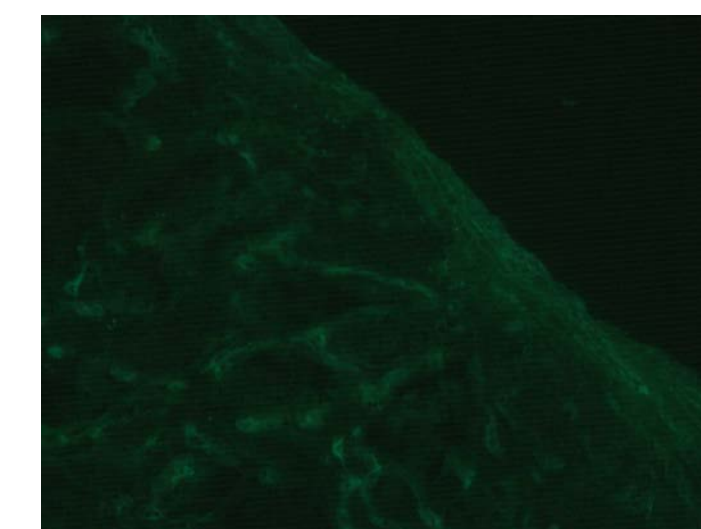
MH is a 27-year-old Hispanic female who underwent a deceased donor renal transplant on June 13, 2016. Her clinical course was uncomplicated. Her original kidney disease was reflux nephropathy. Nadir serum creatinine was 0.7 per protocol. She had a surveillance biopsy 8 weeks post transplant. The biopsy showed evidence of tubulitis in 15% of the specimen as shown in Figure 1. Her serum creatinine was 0.71. She was treated with high-dose steroids. A follow-up biopsy one month later showed no evidence of rejection. C4d staining was negative as was SV 40 stain for BK virus. At last follow-up, her serum creatinine was 0.65.



Tubulitis

CASE STUDY 2

Ms. RR is a 53-year old Hispanic female who underwent a living related donor renal transplant on April 6, 2016. She had a surveillance biopsy at 8 weeks post-transplant when her serum creatinine was 0.8. Light microscopy was normal. The biopsy was strongly positive for peritubular capillary C4d staining. Donor specific antibodies were absent and her serum creatinine has remained normal at one year post transplant. At 6 months, her renal function remains excellent without proteinuria.



Peritubular capillary C4d staining

CONCLUSIONS

Surveillance biopsies are safe and provide valuable information to management of kidney transplant. C4d positivity was common (12.5%) in surveillance biopsy samples. Long term outcomes will ultimately determine the utility of our surveillance protocol.

REFERENCES

1. O'Connell PJ, et al. Biopsy transcriptome expression profiling to identify kidney transplants at risk of chronic injury: a multicenter, prospective study. *Lancet* 2016; 388:983-993.
2. Kee TY, et al. Treatment of subclinical rejection diagnosed by protocol biopsy of kidney transplants. *Transplantation* 2006, 82:36-42.